

ARCH Replacement in Acute Aortic Dissection Type a in Normothermia

OVIDIU STIRU^{1,2}, ROXANA CARMEN GEANA^{1,2}, ADRIAN TULIN^{1,2},
RALUCA GABRIELA IOAN^{1,2}, VICTOR PAVEL^{1,2}, DANIELA GABRIELA BALAN²,
VLAD ANTON ILIESCU^{1,2}

¹Prof. Dr. C. C. Iliescu Emergency Institute for Cardiovascular Diseases Bucharest, 258 Sos. Fundeni, 022328, Bucharest, Romania

²Carol Davila, University of Medicine and Pharmacy, 37 Dinisie Lupu Str., 020021, Bucharest, Romania

Abstract. *The purpose of this case presentation is to present a simplified surgical technique when in a patient with acute aortic dissection type A (AAD), aortic arch, and ascending aorta is completely replaced without circulatory arrest. A 67-year old male was presented in our institution with severe chest and back pain at 12 h after the onset of the symptoms. Imaging studies by 3D contrast-enhanced thoracic computed tomography (CT-scan) and transesophageal echocardiography (TEE) revealed ascending aortic dissection towards the aortic arch, which was extending in the proximal descending aorta. We practiced emergency median sternotomy and established cardiopulmonary bypass (CBP) between the right atrium and the right femoral artery with successive cross-clamping of the ascending and descending aorta below the origin of the left subclavian artery (LSA). In normothermic condition without circulatory arrest and with antegrade cerebral perfusion, we replaced the ascending aorta and aortic arch with a four branched Dacron graft. Patient evolution was uneventful, and he was discharged, after fourteen days from the hospital. At a one-year follow-up, 3D CT-scan showed no residual dissection with a well-circulated lumen of the supra-aortic arteries. Using the described surgical approach, CPB was not interrupted, the brain was protected, and hypothermia was not used. This approach made these surgical procedures shorter, and known complications of hypothermia and circulatory arrest are avoided.*

Keywords: *Acute aortic dissection aortic type A, total arch replacement, normothermia*

1. Introduction

Treatment of AAD represents must be done in an emergency due to the potential for unfavorable evolution to death by myocardial infarction, pericardial tamponade, or stroke [1]. Repair of aortic arch dissection presents a formidable challenge both for surgeons or for the endovascular teams. Open aortic arch repair in AAD remains the standard, but endovascular technology in many centers is a highly selective, infrequently used approach [2]. In recent years experiences with endovascular technology continue to evolve with encouraging early outcomes and expanding indications [3]. Total endovascular arch repair in an emergency may be achieved by the use of parallel stents or in situ fenestration [4]. Unfortunately, the angulation and position of the dissected aortic arch and vessels and the presence of atherosclerotic diseases, make a problematic seal-zone for stent-graft deployment and during endovascular manipulation also a significant stroke. So, nowadays, the best results were reported when aortic arch dissected was replaced on CBP in moderate hypothermic circulatory arrest with antegrade selective cerebral blood perfusion protection. Cerebral protection is essential to obtain encouraging results, debates between maintaining cerebral perfusion are in favor of antegrade cerebral

*email: ovidiu_stiru@yahoo.com

All authors contributed equally to the present work and thus are main authors

perfusion (ACP) instead of retrograde cerebral perfusion (RCP), and also in support of using moderate hypothermia instead of profound hypothermia. There are only a few reports about aortic arch replacement in normothermic conditions [5-7].

2. Materials and methods

We present the case of a 67-year-old male patient transferred to our clinic with severe chest and back pain onset 12 h before admission. On admission, he was stable, his heart rate was 80 bpm, and his systemic blood pressure was 135/90 mmHg, peripheral oxygen saturation was 93% in room air. He showed signs of mild confusion, but he was able to communicate. He has diagnosed with Stanford type A acute aortic dissection, and we planned to perform an aortic root replacement with a composite graft. He reported untreated systemic hypertension. He has transferred to the intensive care unit (ICU) hemodynamic stable. Transthoracic echocardiography (TTE) found normal left ventricular function without any apparent regional wall motion or valvular abnormality. Transesophageal echocardiography (TEE) revealed an intimal flap on ascending aorta, aortic arch, and the first portion of descending aorta. CT-scan angiography revealed the presence of a dissection surrounding ascending aorta, aortic arch, and descending aorta until iliac bifurcation without signs of rupture or active bleeding (Figure 1). Doppler ultrasound assessment of femoral and supra-aortic vessels showed permeable arteries without dissection. We diagnosed the condition as an AAD and sent the emergently to the operating theatre, where we planned to perform an ascending aorta and aortic arch replacement with a branched Dacron graft. We used specific monitoring for aortic arch surgery that included: monitoring of the rectal and esophageal temperature during CPB, intra-arterial blood pressure monitoring the left radial artery and the right femoral artery and near-infrared spectroscopy (NIRS) for reflecting cerebral oxygenation of the frontal cortex to detect any potential cerebral malperfusion.

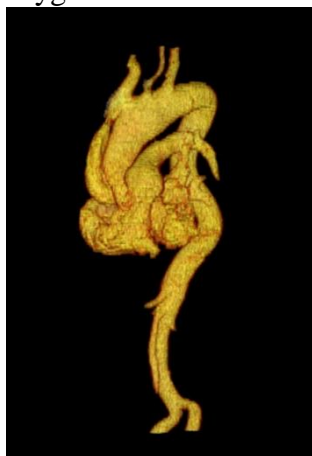


Figure 1. CT-scan revealed the presence of a hematoma surrounding the aortic arch, without signs of rupture or active bleeding

During the surgical procedure, we exposed the ascending aorta and aortic arch through a median sternotomy. We performed careful dissection of the supra-aortic arch branches and the proximal segment of the descending aorta, without the need to divide or to ligate the brachiocephalic vein. We identified and isolated the innominate artery, the left common carotid artery and the left subclavian artery as well as the proximal portion of the descending aorta. We established CPB between the right femoral artery and the right atrium. We used one main arterial line and two secondary arterial lines. The main arterial line was passing through the cardiopulmonary bypass machine, providing, via the right femoral artery, the body's perfusion. The second two arterial lines, which were passing through also the cardiopulmonary bypass machine and two independent pumps provided the cerebral perfusion. We could monitor the flow and the pressure of the delivered blood, separately for both secondary lines. Each branch of the second line was connected with a separate retrograde cardioplegia cannula and with a monitoring line for pressure. We were venting the heart through the right superior pulmonary vein and started CPB. The ascending aorta was cross-clamped. After transversally opening ascending aorta, and myocardial protection was achieved by directly infused a single dose of Custodiol cardioplegia,

the aortic root, valve leaflets, the integrity of Valsalva sinuses and both ostial coronary orifice, were carefully inspected for the existence of the intimal dissection and was considered to be conservable. After dissection of the first portion of descending aorta, we cross-clamping descending aorta at a minimum of two cm below the LSA origin. After that we removed the dissected ascending aorta distal from the sinotubular junction and entire aortic arch. Supraaortic arch vessels (Left common carotid artery and brachiocephalic arterial trunk) detached from the aortic arch were translated in front of the brachiocephalic vein and was cannulated to provide selective antegrade cerebral perfusion for brain protection. The origin of the left subclavian artery (LSA) is also detached from the aortic arch. Selective antegrade cerebral perfusion was started using both secondary arterial lines, with normothermic blood. The brain was protected using selective perfusion with a flow of 10 mL/kg/min permanent adjusted to maintain for each pump a delivery pressure between 55 to 75 mm Hg. In the meantime, we continuous monitoring of the NIRS in both the frontal cortex. During selective antegrade cerebral perfusion, we clamped LSA. We start in the beginning with the distal anastomosis between the main body of the No. 28, four-branched woven Dacron graft, and the descending aorta. After performed the distal anastomosis, the cross-clamping the main body Dacron graft. After trim appropriate Dacron graft length, the next anastomosis performed is between the remaining body end of the Daron graft and the sinotubular junction of ascending aorta. After performing the last anastomosis and de-airing the cardiac chambers, we removed the cross-clamp over the body Dacron graft. Successive we performing anastomoses between the branch of the Dacron graft and IA, LCCA, and the LSA (Figure 2). The time of CPB was 118 min, aortic clamp time was 61 min, and the time of antegrade selective cerebral perfusion was 82 min. The first preoperative day blood loss was 450 mL, and the patient was extubated at 48 h. He developed mild transient neurological dysfunction, with cerebral CT examination that did not reveal any ischemic or hemorrhagic cerebral lesions. The intensive care unit stay was three days long. The patient was discharged after two weeks, and follow up one year 3D contrast-enhanced computed tomography (CT) angiography showed no residual dissection of the supra-aortic vessel and descending aorta (Figure 3).

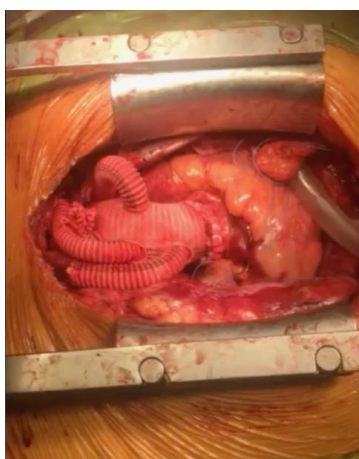

Figure 2. Intraoperative view of total aortic arch replacement with 4-branch gelatin-impregnated Dacron prosthesis

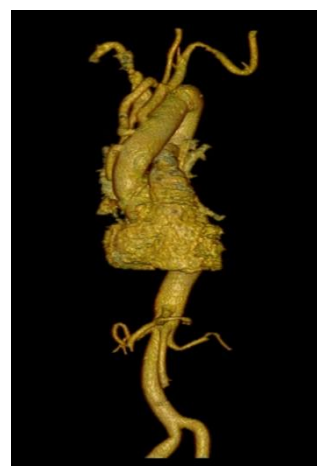

Figure 3. CT-scan showed no residual dissection of the ascending aorta

2. Results and discussions

Surgery for aortic arch replacement in AAD carries a significant risk of mortality and stroke [8]. The surgeon's primary concern is to minimize the mortality rate, and for the surviving patients to



reduce the risk of developing neurological complications. Over time, strategies for aortic arch replacement run together with a plan for cerebral protection. Nowadays, success regarding minimizing neurologic complication in arch replacement surgery is due to a preference towards antegrade cerebral perfusion at 22–26 °C in AAD (91%), with predominantly axillary/subclavian cannulation [9]. However, the superiority benefit of normothermic CPB over hypothermic CPB in cardiac surgery also is known [10,11]. Discussion about the route of cerebral perfusion indicates that antegrade selective cerebral perfusion is superior to retrograde cerebral perfusion. However, a proper protocol for antegrade cerebral protection, such as what is the optimal flow cerebral rate or what is the perfusion pressure and temperature, is still debated, and each institution has its protocol and recommendations for this approach [9,11].

Therefore, to maintain maximal cerebral perfusion, proper cerebral blood flow has to be achieved. Cerebral blood flow represents 15% of the total cardiac output. The brain tissue requires approximately 50 mL of blood/100 g, which means that for a healthy brain of 1200-1400 g are necessary at least 600-700 mL of blood to sustain normal cerebral perfusion [6]. Thus, selective antegrade cerebral perfusion must be administrated a minimum volume of 600-700 mL blood into both carotid arteries, which is distributed by self-regulation in a proportion of 4/1 between grey matter and white matter. A 30% reduction in the cerebral flow interferes with this distribution and causes selective hypoperfusion for one of the brain matters leading to neurologic dysfunction [7]. Discussion about the temperature of cerebral perfusion remains controversial. The brain temperature under 20 degree C appears to be potentially harmful because of an increase in the cerebral vascular resistances, and self-regulation is affected and appears a risk of excessive cerebral perfusion in grey matter and insufficient cerebral perfusion in white matter. Therefore, it is easy to deduce that only circulatory arrest, even in profound hypothermia, is not today an option; this approach leaves all patients different degrees of neurological dysfunction. Nowadays, the best results regarding neurological complications were reported in arch replacement in circulatory arrest with antegrade selective cerebral blood perfusion at 28 degrees Celsius with a pressure of cerebral perfusion between 55-75 mm Hg with continuous bilateral measuring NIRS in the frontal cortex [12]. NIRS level may identify cerebral desaturation and the patient's risk for developing postoperative neurological dysfunction. Any changes in the value of NIRS enforce emergency measures, and first of all, only changing the position of the perfusion cannula inside the affected carotid artery can lead to regaining a standard value (between 55-75 mm Hg [13]. Hence, NIRS provides the opportunity to optimize cerebral blood flow by increasing PaCO₂, arterial pressure, or perfusion pressure (below 75mmHg), FiO₂, and hematocrit [13]. In some cases, the absence of LSA origin enables better visualization and enhances the hemostasis of the distal anastomosis.

Nevertheless, hypothermia itself raises concerns about the coagulation system [inverse relationship between the incidence of bleeding and temperature] and inflammatory response [4]. Cooling and warming the patient prolong the total time of CPB and increases the risk of systemic complications [13]. Our approach avoids all these complications. Normothermia appears to be the next step in cerebral protection, allowing more physiological autoregulation of cerebral blood flow. However, endovascular aortic arch repair in AIMH remains in the most center a highly selective, infrequently used approach. The hybrid approach combines the most innovative aspects of open and endovascular repair and is also in many centers occasionally used. Open surgery with Dacron branches graft is now a valid option, and the normothermic approach is the next step for improving morbidity in cerebral-protection techniques. Nevertheless, the results of normothermic strategies in aortic arch replacement remain to be determined.

3. Conclusions

Aortic arch replacement in normothermic conditions in acute type A aortic dissection is a safe technique, the main advantage is shortening the time operation, and through the absence of a circulatory arrest, all the complications of this approach are inexistent. We consider this technique to

be curative, with no possibility of occurrence of progression of residual dissection in the supra-aortic arch vessel and the descending aorta.

Abbreviation:

Antegrade cerebral perfusion ACP
Cardiopulmonary bypass CPB
Computed tomography angiography CT-scan
Near-infrared spectroscopy NIRS
Left subclavian artery LSA
Left common carotid artery LCCA
Intensive care unit ICU
Retrograde cerebral perfusion RCP

References

1. ILIESCU, VA., et al. Combined cardiac neurosurgical treatment of acute aortic dissection, stroke, and coma. *Texas Heart Institute Journal* 35, nr. 2, 2008, p. 1-3.
2. HORTON, JD. et al. Endovascular repair of type A aortic dissection: current experience and technical considerations. *Semin Thorac Cardiovasc Surg* 28, 2016, p. 312-317.
3. STIRU, O., GEANA, R., PAVEL, P., CROITORU, M., et al. Descending Thoracic Aortic Aneurysm Rupture Treated with Thoracic Endovascular Aortic Repair in a Patient with Peripheral Artery Disease. *The Heart Surgery Forum*, 21(2), 2018, E112-E116.
4. KAMIYA H, HAGL C, KROPIVNITSKAYA I, BÖTHIG D. et al. The safety of moderate hypothermic lower body circulatory arrest with selective cerebral perfusion: a propensity score analysis. *J Thorac Cardiovasc Surg* 133, 2007, p. 501-509.
5. TOUATI, GD, et al. Totally normothermic aortic arch replacement without circulatory arrest. *European Journal of Cardio-thoracic Surgery* 32, 2007, p. 263-269.
6. NARIHIRO ISHIDA, et al. Normothermic total arch replacement without hypothermic circulatory arrest to treat aortic distal arch aneurysm in a patient with cold agglutinin disease. *Interactive CardioVascular and Thoracic Surgery* 13, 2011, p. 432-434.
7. DIRNAGL U, et al. Autoregulation of cerebral blood flow in experimental focal brain ischemia. *J Cereb Blood Flow Metab* 10, 1990, p. 327-336.
8. STIRU, O., GORDUZA, VE., et al. Surgical management of type A acute aortic dissection in patients with Marfan syndrome: A single center experience. *Rev. Med. Chir. Soc. Med. Nat., Iași* vol. 120, no.3, 2016, p. 611-618
9. DE PAULIS, R. CZERNY, M. WELTERT, L. BAVARIA, J. BORGER, M.A. CARREL, et al. Current trends in cannulation and neuroprotection during surgery of the aortic arch in Europe. *Eur J Cardiothorac Surg* 47, 2015, p. 917-923.
10. GRIMM M, CZERNY M, BAUMER H, KILO J, et al. Normothermic cardiopulmonary bypass is beneficial for cognitive brain function after coronary artery bypass grafting - a prospective randomized trial. *Eur J Cardiothorac Surg* 18, nr. 3, 2000, p. 270-275.
11. GRIGORE AM, MATHEW J, GROCOTT HP, REVES JG, et al. Prospective randomized trial of normothermic versus hypothermic cardiopulmonary bypass on cognitive function after coronary artery bypass graft surgery. *Anesthesiology* 95, 2001, p. 1110-1119.
12. SVEN PETERSSA, MAXIMILIAN PICHLMAIERA, ALEXANDER CURTISC, MAXIMILIAN LUEHRA et al. Patient management in aortic arch surgery *European Journal of Cardio-Thoracic Surgery* 51, 2017, p. i4-i14.
13. MURKIN, JOHN M., ADAMS, SANDRA; NOVICK, RICHARD J., et al. Monitoring brain oxygen saturation during coronary bypass surgery: a randomized, prospective study. *Anesth Analg* 104, 2007, p. 51-58.

Manuscript received: 20.03.2020